GAU Research Journal **48** (2) : 156-168 (April 2023)

Toxicity Assessment of Micronutrients on the Physiological Potential of Freshwater Indian Major Carp, *Labeorohita*

Indu Kumar [1] and Sneha Verma[2]*

[1&2]Department of Science, Maharishi School of Science and Humanities, Maharishi University of Information Technology, Lucknow, U.P., India
*Email: drsnehaverma@yahoo.com

ABSTRACT

The present investigation was planned to observe various toxicological changes of heavy metals copper and zinc on freshwater Indian major carp *Labeorohita*. The main objectives were to investigate the LC_{10}, LC_{25} and LC_{50}concentrations of copper and zinc for *L. rohita* and its impact on haematological and histological alteration of the vital organs (liver, gill and kidney). The findings showed a significantly increased fatalitypercentage as toxicant concentrations escalated ($F=1347.21$; $p<0.05$: for copper, and $F=754.37$; $p<0.05$: for zinc). Fish was more sensitive towards zinc toxicity ($R^2=0.947$) as compared to copper ($R^2=0.924$). The haematological study revealed that the short-term and long-term toxicity of heavy metal resulted in significant decreases in Hb %, RBC count and PCV value, with the exception of increased WBC count, MCV, MCH and MCHC values. The histopathology findings demonstrated that fish exposed toheavy metals for an extended period of time at lower concentrations and at higher concentrations had more severe and frequent organ lesions with several alterations and degenerations.

Keywords: Copper, Haematological indices, Histopathological changes, Labeorohita, LC_{50}, Zinc

INTRODUCTION

Aquatic bodies may be extensively contaminated with heavy metals due to technological innovation, industrial expansion, and anthropogenic activities. Heavy metals are known to be potent biological poisons due to their persistence, non-biodegradability, toxicity, and propensity to accumulate in organisms and go through biomagnification. Among the heavy metals, Zn and Cu are the most prevalent required micronutrients that play a key role in growth, reproduction, development, cardiac function metabolism, and immune system catalysis(Hedayatiet al*.,* 2013; Guoet al*.,* 2022). They are highly toxic at higher concentrations, causing damage to numerous organs such as the gills, kidneys, and spleens, impairing osmoregulation, and causing teratogenicity and chromosomal abnormalities(Fahmy, 2000; Grosell *et al.*,2002).

Fish exhibit a variety of physiological reactions, including blood pressure fluctuations, concerns with ion regulation, difficulties with oxygen intake, and assessments of their health in response to pollution exposure. Calculating the LC_{50}, or the amount of a toxin in a lethal concentration (LC) that will kill 50 per cent of

the test animal population in a given amount of time, is the best technique to test for acute toxicity. Haematological and histological measures, which have been frequently employed as helpful biomarkers to assess the environmental change, stress or toxicity of any xenobiotics, are of particular importance in terms of toxicity bioassay parameters. Blood carries the majority of the metals that a fish organism absorbs throughout its body(Akahori et al.,1999). Metal that has been ingested by fish through a number of organs is then delivered by the blood to the liver. There, it may be kept, discharged in bile, returned to circulation for potential excretion by the kidney or gills, or retained in extrahepatic tissues like fat. Heavy metals consequently accumulate through circulation into a variety of fish tissues, resulting in anatomical, morphological, histopathological, and biochemical alterations in several tissues that may severely reduce fish quality (Olojo *et al.*, 2005; Fadel and Gaber, 2007).

Indian major carp, *Labeorohita* is most widely used in research works because it is capable to absorb, adapting nature to the laboratory condition and fixing the toxic metals from the adjacent. The knowledge of the heavy metals (copper and zinc) toxicity in the physiology of Indian major carp is meagre. Consequently, the main objective of the present study is to determine the impact of different concentrations of copper and zinc in Indian freshwater carp *Labeorohita* using haematological profiling viz., Hb, RBC, WBC, PCV, MCV, MCH, and MCHC, and histology of the vital organs (liver, gill and kidney).

MATERIALS AND METHODS

A. Estimation of median lethal concentration

Healthy fish of uniform weight and length were chosen for the toxicity testing. The varied concentrations of Cu and Zn were chosen for the study (0.25 mg/l to 6 mg/l: Cu and 5 mg/l to 35 mg/l: Zn). Concurrently, the control group was also kept active. To ensure consistency, ten animals were used to evaluate each concentration's effects in triplicate. Fish mortality was measured at logarithmic time intervals, in order to determine the LC50 for each interval. In order to keep the hazardous level in a constant condition, all solutions (control and test) were routinely refreshed (often at intervals of 24 hours). Dead fish were removed immediately. Throughout the trial, fish were not fed. At the completion of the exposure duration, the fish were immediately sacrificed. The biochemical and histological contents (gill, kidney, and liver) were examined in the context of heavy metal toxicity.

B. Estimation of Haematological content

1. Sampling of Blood

After determining 96 h LC_{50} value of Zn and Cu, fishes were exposed to 96 h LC_{50} for 15 and 30 days. After the exposure period, blood was drawn from the caudal vessels using an insulin syringe and a 22-gauge needle while using EDTA (ethylenediaminetetraacetate) as an anticoagulant. Haemoglobin content was measured by Sahli's haemoglobinometer. The microhaematocrit method(Snieszko, 1960) was used to determine PCV. RBC and WBC were counted under the light microscope using an improved Neubauer hemocytometer and calculated using the given formulae *viz.*, (No. of cells x Dilution factor x Depth factor)/ Area counted. The mean corpuscular volume (MCV: μm^3) was calculated as (PCV x 100) / RBC in million, mean corpuscular haemoglobin (MCH) as

Hb(g/dl) x 100 / RBC in million and mean corpuscular haemoglobin concentration (MCHC) by Hb (g/dl) x 100 /PCV (%).

A. Process of Histological Assessment

At the end of the duration experiment of Zn and Cu toxicity (96h of LC_{50} for 15 and 30 days), the desired tissue (gill, Kidney and liver) was dissected and fixed in Bouin's fixative for 24 hr. The tissues were then embedded in paraffin after being dried using a graduated ethanol series. Weswox's rotary microtome was used to cut tissue into sections that were 6-7 µm thick, and further it was stained with hematoxylin and eosin.The stained histological sections of various tissues were further examined under the microscope to study the effect of the test chemical (Zn and Cu).

B. Data analysis

The fish mortality was presented in percentage. It was recorded every 24 hr up to 96 hr study period. The data were analyzed statistically by one-way analysis of variance (ANOVA). The median lethal and sub-median lethal concentrations (LC_{10}, LC_{25} and LC_{50}) with 95% confidence limits were estimated by probit analysis(Finney, 1971) with the statistic software (IBM SPSS version 20). The histological sections of Gill, Kidney and Liver tissues were examined at 10X magnification under the brightfield microscope (Olympus).

RESULTS AND DISCUSSION

1. Lethal toxicity tests

The freshwater Indian carp, *Labeorohita*, was shown to be highly poisonous to copper than zinc, according to the current result. Fish showed varied degrees of mortality to different concentrations of copper and zinc. The mortality was significantly increased with the concentrations at 96 hr duration of the experiment (F=1347.21- Copper, F=754.37- Zinc*; p*<0.05). In lower concentrations of copper (0.25 mg/l) and zinc (1 mg/l), fish showed 0% mortality and at higher doses of copper (6 mg/l) and zinc (35 mg/l) toxicant showed 100 % mortality in 96 hr exposure duration (Figure 1). Based on the mortality, LC_{10}, LC_{25} and LC_{50} values were calculated by probit analysis (Table 1). The regression analysis resulted that zinc toxicity analysis showed R^2=0.947 and copper showed R^2=0.924 value which interpreted that zinc followed the goodness of fit measure and showed a high level of correlation as compared to copper (Figure 1). Similar observations were discovered by many researchers(Ciji and Nandan, 2013; Wepener *et al.*, 2001; Dhanapakiamet al.,2006). Chinni and Yallapragda (2000) performed an acute toxicity test on *Penaeus indicus* post larva with Pb, Zn, Cd & Cu heavy metals and obtained 96h LC_{50} and concluded that copper (2.535 mg/l) was most toxic among all other heavy metals. Present findings nearly correspond with the LC_{50} value of zinc in several fishes like in *Clariaslazera* (12.25 mg/l), *Cnesterodondecemmaculatus* (12.40 mg/l), *Parophrysvetulus* (14.50 mg/l) and *Clariasbatrachus* (17.22 mg/l)(Shenker and Cherr, 1990; Annune *et al.*, 1992; Joshi, 2011).

2. Haematological parameters

The exposed fish to sub-lethal concentrations of copper and zinc showed decreased Hb, RBC, PCV, and increased WBC, MCV, MCH and MCHC concentrations in short-term and long-term duration exposure as compared to control. The short-term exposure(15 days of 1/10th of 96 hr LC_{50}: 0.25 mg/l) of copper toxicant showed decreased Hb% (4.96±0.07), RBC count (1.09±0.18x10^{6}cells/mm^3) and PCV% (31.99±1.12), and increased WBC count

(21.07±1.16x10^{3}cells/mm^3), MCV (94.25±1.49 µm^3), MCH (42.68±1.1pg) and MCHC (35.77±1.15 %). The same pattern of observations was recorded in long-term exposure (30 days of 1/25th of 96 hr LC_{50}: 0.102mg/l) of copper. It showed 4.84±0.17 % Hb, 0.68±0.33 x 10^6/mm^3 RBC, 32.01±0.51 x 10^3 cells /mm^3 WBC, 28.57±0.82 % PCV, 96.08±1.67 µm^3 MCV, 45.65±0.53pg MCH and 31.87±1.09 % MCHC.

The zinc-exposed fish showed low values of haematological indices as compared to copper-exposed fish. It showed 4.61±0.12% Hb, 1.77±0.55 x10^{6}cells/mm^3 RBC, 28.43±1.37 x 10^3 cells /mm^3 WBC, 33.38±1.12 % PCV, 94.67±0.24 µm^3 MCV, 43.29±1.3 pg MCH and 34.17±1.21 % MCHC in short term exposure for 15 days (1/10th of 96 hr LC_{50}: 1.99 mg/l). The long-term exposure for 30 days (1/25th of 96 hr LC_{50}: 0.79 mg/l) of zinc induced increased haematological indices such as 4.42±0.02% Hb, 1.61±0.63 x10^{6}cells/mm^3 RBC, 34.48±1.09 x 10^3 cells /mm^3 WBC, 28.62±1.87 % PCV, 98.32±1.52 µm^3 MCV, 47.89±1.68 pg MCH and 32.59±1.93 % MCHC (Table 2; Figure 2).

The exposure to copper and zinc significantly affected Hb%, RBC, PCV, and increased WBC, MCV, MCH, and MCHC content, which is consistent with other scientific findings (Griffin *et al.*, 1999; Kori-Siakpere and Ubogu, 2008; Dutta *et al.*, 2016). Intestinal iron absorption is hindered by heavy metal exposure, resulting in hypochromic anaemia which decreases RBC, PCV and Hb content(Joshi et al., 2002). Suganthi et al. (2015) showed that the hemolysis of blood cells reflects changes in Hb and PCV count, and decreased total RBC count in *O. mossambicus*, exposed to different concentrations of ZnO(30-70ppm). According to Hoq and Haque (2014), the decline in RBC count was also caused by a failure to produce erythrocytes, internal hemorrhages, or decreased osmoregulation under stressful conditions, which led to a decrease in Hb and PCV content and confirmed intravascular hemolysis in the blood arteries of the liver and kidney.

According to John (2007), the fish's leucocytosis defensive mechanism response to diseased conditions and foreign materials may account for the abrupt rise in WBC count. Additionally, it denotes leukemia, hypersplenism, inflammation, and damage brought on by bacterial infections of bodily tissues (Nordenson, 2004).In the current study, a significant increase in MCV and MCH indicates to red blood cell swelling or a decline in TEC values, both of which were associated with macrolyticanemia (Ghalazy, 1992; Raina and Sachar, 2014; Parmila and Rajan, 2020An increase in MCV was also observed in fish treated with xenobiotics, according to Gupta et al. (2009). A drop in cellular blood iron may be the reason for the MCH's considerable shift, which would then affect the blood's capacity to carry oxygen and induce erythropoiesis (Hodson *et al.*, 1978). The higher MCHC values showed that heavy metals applications to fish may be caused macrocytic anemia (Celik *et al.*, 2013). According to Ramesh *et al.* (2014) and Abdel Khalek et al. (2016), the change in MCH and MCHC could be due to anemia brought on by production in the hemopoietic tissues under the influence of the deposited metal oxide, RBC hemolysis, or both. Similar outcomes were observed in *O. mossambicus*treated to zinc (Nussey *et al.*, 2002) and *Clariasalbopunctatus* exposed to organophosphorus insecticide (Mgbenka *et al.*, 2005). The generation of oxygen is

reduced by the high dose of heavy metals, which prevents macrophage activation, motility, and phagocytosis. The immune-suppressing effects of heavy metals in fish have been documented in numerous research (Sampath et al., 1998; Witeska, 2005; Kori-Siakpere and Ubogu, 2008).

3. Histopathological study

In the present investigation, fish exposed to copper and zinc toxicants had a variety of histopathological alterations found in their gill, kidney, and liver tissues. Fish treated with higher quantities and even low concentrations of heavy metals with prolonged exposure showed more severe and frequent organ damage. The observations of histopathological analysis showed that heavy metals caused vacuolation, fusion of primary gill lamellae and inter lamellar space, degeneration of gill lamella, separation of the basement membrane, necrosis, desquamation, cellular swelling, and blood congestion. In the secondary lamellae, there were sclerotic and necrotic gill arches, few mucous cells, and no chloride cells among the epithelial cells. Prolonged exposure caused telangiectasia of the primary and secondary lamellae, which was characterized by hyperplasia of concentric rings, histolysis of the primary lamellae, mucous gland, dispersed gill lamellae, and blood cells. Numerous researchers have also documented the same findings (Ortiz et al., 2003; Mishra and Mohanti, 2008). Lamellar fusion may be protective because it minimizes the exposed gill surface area (Ortiz et al., 2003), whereas epithelium lifting or detachment of epithelial cells (chloride cells, pavement cells) lengthens the route taken by the toxin to enter the bloodstream and impairs oxygen uptake (Kumar *et al.*, 2010).

The study of the kidney's histological structure showed degenerated renal tubules and bowman capsules. The epithelial cells lining the renal tubules exhibited severe degranulation hypertrophy, resulting in tubular lumen shrinkage. Vacuolization of epithelial cells was found, as well as damage to hematopoietic tissues. There was also dilation, oedema, and hypertrophied nuclei of renal tubules. Glomeruli were found to have vacuolization and disordered blood capillaries. By the 30th day, the damage had become more evident and severe. Similar results have been seen in *Clariasbatrachus, Cyprinus carpio, Oreochromis mossambicus* and *Oreochromis niloticus* exposed to heavy metals such as copper sulfate, zinc chloride and zinc sulphate (Figueiredo-Fernandes *et al.*, 2007; Vinodini and Narayan, 2009; Hoq and Haque *et al.*, 2014). Gupta and Srivastava (2006) also noted vacuolation, abnormal nuclei orientation, desquamation in renal tubule epithelial cells, and reduction of glomerular tuft and capsules.

The parenchymal architecture of the hepatocytes was also altered which resulted in inflammation, hepatocyte rupturing and increased accumulation of pyknotic nuclei, clumping, nuclei condensation, vacuolization of tissue, as well as several foci of coagulative necrosis and blood vessel degeneration. Cirrhosis developed when the entire tissue became necrotic. Hepatocytes in the treated liver had smaller nuclei with compacted nuclear chromatin more commonly. The central vein had been injured and was heavily vacuolized (Figure 3). The histopathological analysis of the liver showed many studies which demonstrated the same alterations (Abdel-Moneim and Abdel-Mohsen, 2010; Udotong and John, 2015; Abdel-Tawwab, 2016). Hepatocytes often undergo size changes, their nuclei are pushed to the

periphery, and some of the cell membranes are torn, fusion of cells together and the appearance of binucleate or multinucleate cells, cytoplasmic and nuclear degeneration (Pacheco and Santos, 2002).

CONCLUSION

Aquatic ecosystems that run near different agricultural areas have a high probability of being contaminated by runoff and their leaching into groundwater can extend their toxic effects to all aquatic organisms. It is abundantly obvious that the river's metal contamination is ongoing and that this is having an impact on the health of local fish. Despite being harmed histologically, biochemically, and hematologically by river contamination, they continue to thrive. But it is clear that this species will struggle to live if pollution keeps happening in this way. For ecological life to continue functioning, it is crucial that we preserve our natural resources and native species.

Table 1: LC_{10}, LC_{25} and LC_{50} values with its 95% confidence limit (upper and lower limit) at 96 hr exposure period in freshwater Indian major carp *L.rohita* exposed to heavy metal.

Heavy metal	Toxicity parameters	LC10	LC25	LC50
Copper Toxicity	Lethal Concentrations	0.52	1.48	2.55
	Upper Limit	0.82	1.70	2.76
	Lower Limit	0.17	1.23	2.35
Zinc Toxicity	Lethal Concentrations	8.38	13.86	19.94
	Upper Limit	10.91	15.82	21.86
	Lower Limit	4.87	11.41	18.1

Table 2: Blood profiling of exposed freshwater Indian major crap, *L.rohita*to 96 hr LC_{50} for 15 days ($1/10^{th}$ of 96 hr LC_{50}) and 30 days ($1/25^{th}$ of 96 hr LC_{50}) of copper and zinc toxicity.

Parameters	Control	Copper (LC_{50}: 2.55 mg/l)		Zinc (LC_{50}: 19.94 mg/l)	
		15 days (0.25 mg/l)	30 days (0.102 mg/l)	15days (1.99 mg/l)	30 days (0.79 mg/l)
Hb (%)	6.64 ±0.46	4.96 ±0.07	4.84 ±0.17	4.61±0.12	4.42±0.02
RBC (10^6 cells /mm3)	1.71 ±0.49	1.09 ±0.18	0.68 ±0.33	1.77±0.55	1.61±0.63
WBC (10^3 cells /mm3)	12.7 ±0.57	21.07±1.16	32.01±0.51	28.43±1.37	34.48±1.09
PCV (%)	36.02 ±1.79	31.99 ±1.12	28.57 ±0.82	33.38±1.12	28.62±1.87
MCV (µm3)	90.64 ±1.71	94.25 ±1.49	96.08 ±1.67	94.67±0.24	98.32±1.52
MCH (pg)	37.89 ±1.55	42.68 ±1.1	45.65 ±0.53	43.29±1.3	47.89±1.68
MCHC (%)	28.25 ±1.92	35.77 ±1.15	31.87 ±1.09	34.17±1.21	32.59±1.93

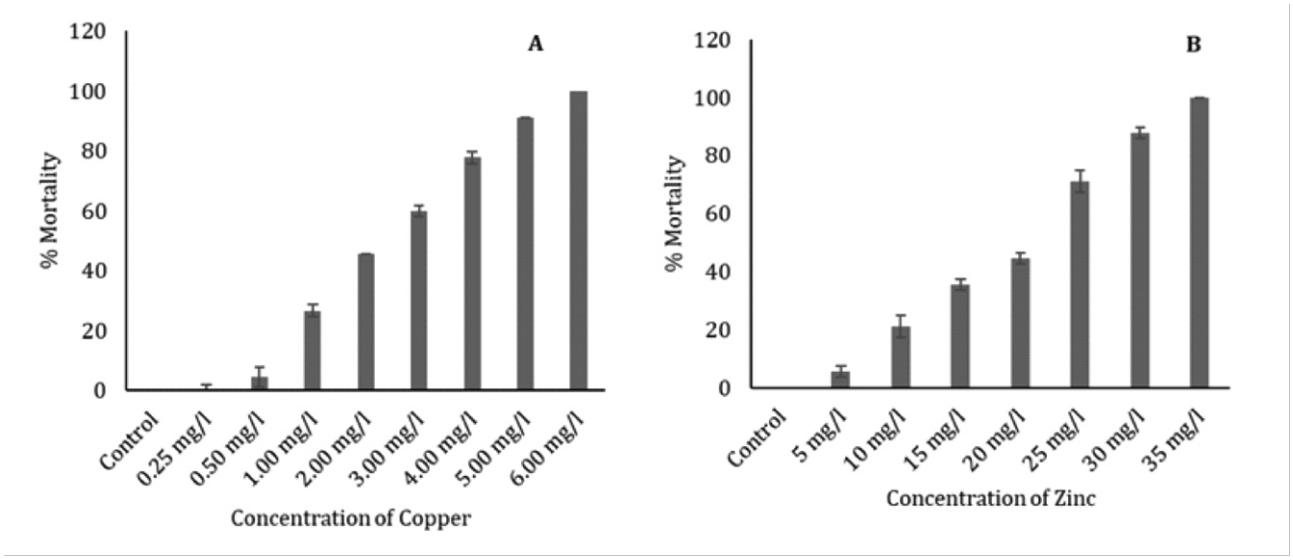

Fig. 1. Effect of varied concentrations of copper (A) and zinc (B) for 96 hr on % mortality of freshwater Indian major carp,*Labeorohita*. Values were represented as means ± SEM of a percentage of mortality. Data were analyzed by one-way ANOVA (p< 0.05). Probit transformed the response of freshwater fish, *Labeorohita* under exposure of copper (C) and zinc (D).

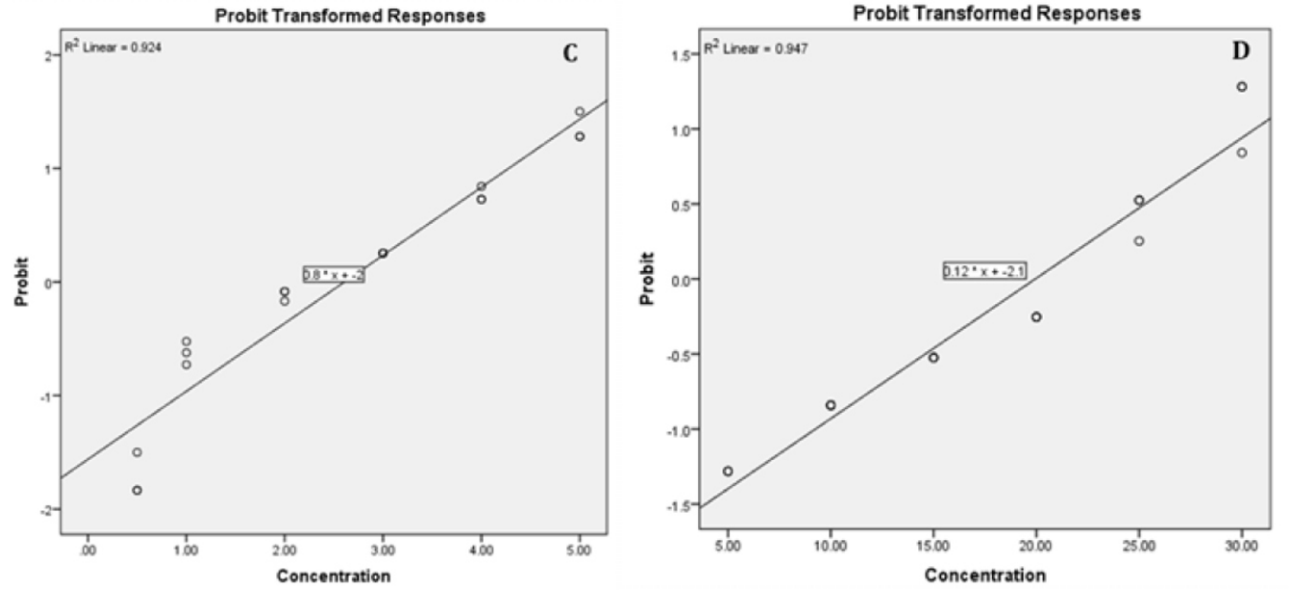

Fig. 2. Short-term (15 days) and long-term (30 days) exposure of sub-lethal concentration of copper (A) and zinc (B) on various haematological indices (Hb, RBC, WBC, PCV, MCH, MCV and MCHC) of freshwater Indian major carp,*Labeorohita*. Values were represented as means ± SEM of a percentage of mortality. Data were analyzed by one-way ANOVA (p< 0.05).

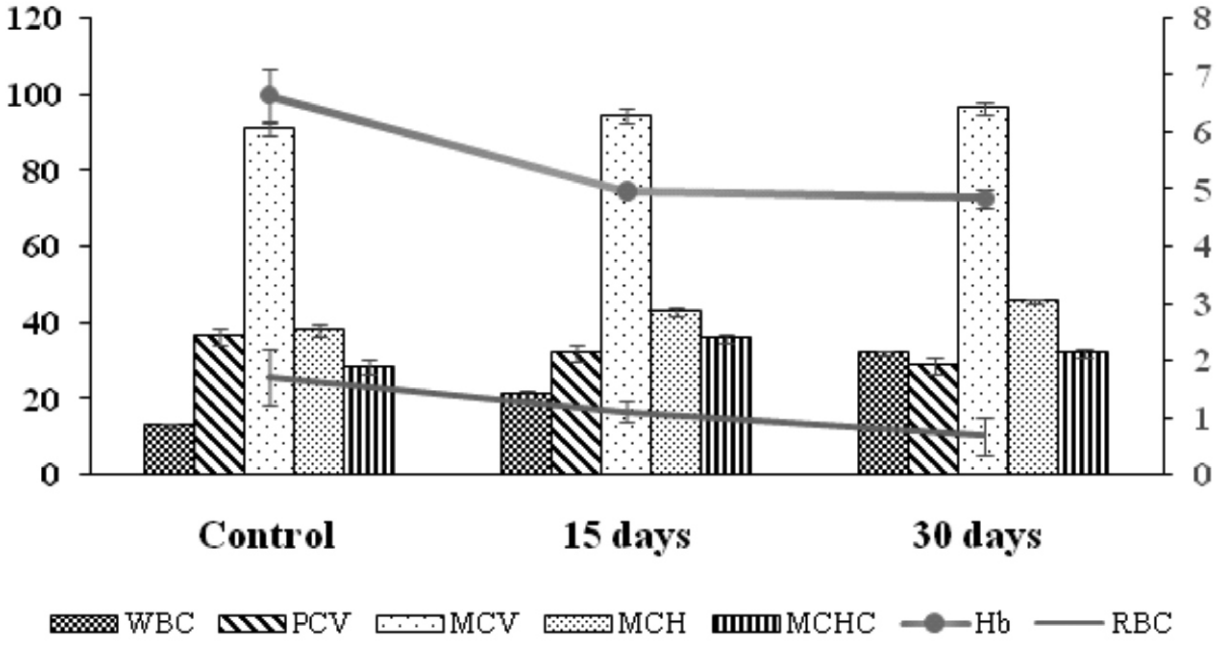
120
100
80
60
40
20
0
8
7
6
5
4
3
2
1
0
Control
15 days
30 days
WBC
PCV
MCV
MCH
MCHC
Hb
RBC

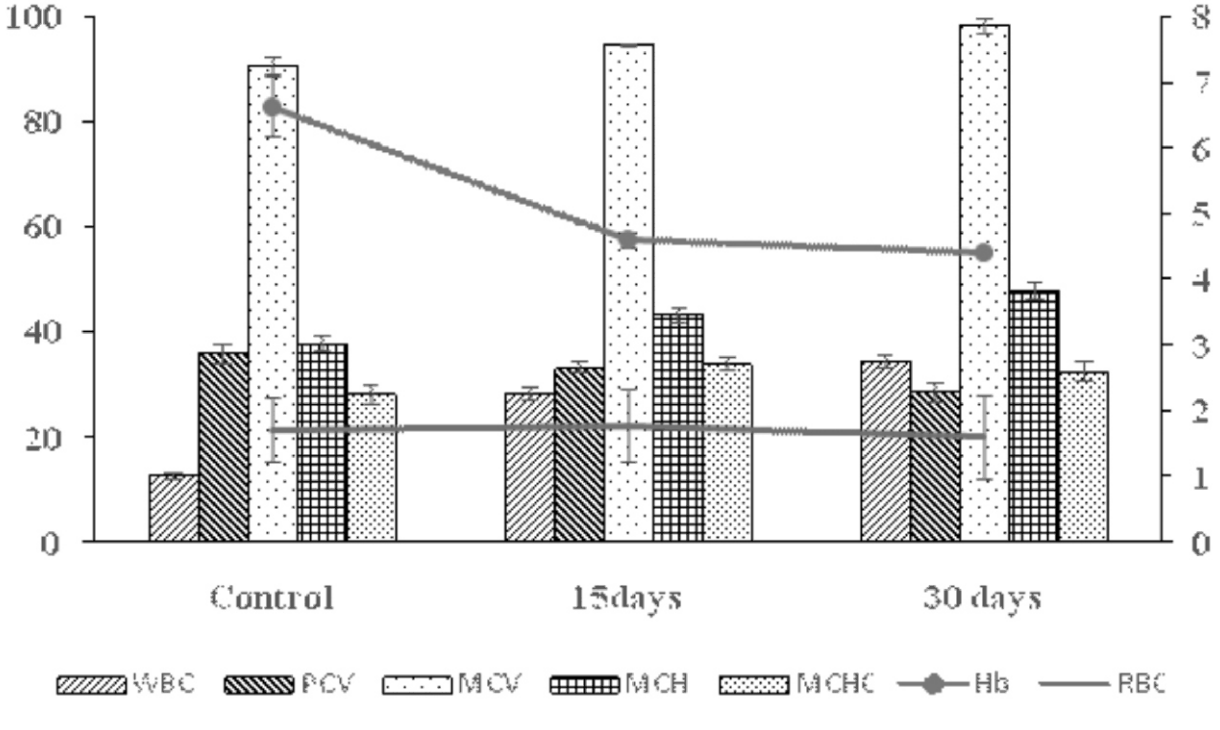
100
80
60
40
20
0
8
7
6
5
4
3
2
1
0
Control
15days
30 days
WBC
PCV
MCV
MCH
MCHC
Hb
RBC

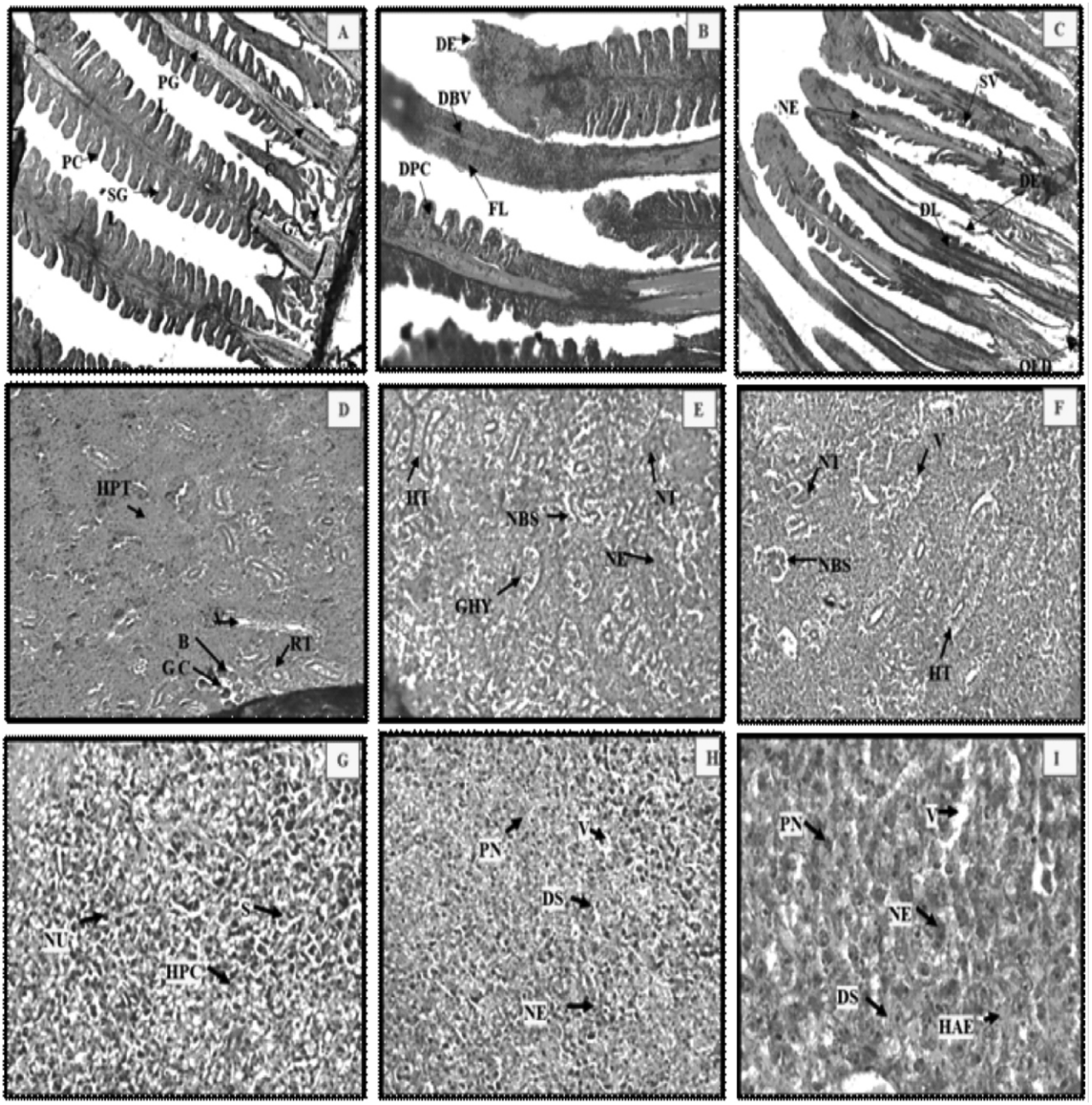

Fig. 3. Photomicrograph of histological sections of gill (A, B, C), kidney (D, E, F) and liver (G, H, I) of fish*Labeorohita* was shown using haematoxylin & eosin stain, represented sections of control fish (A: gill, D: kidney, G: liver) and exposed fish to 30 days to 96 hr LC_{50} of copper (1/25th of 96 hr LC_{50}-0.102mg/l: B, E, H) and zinc (1/25th of 96 hr LC_{50}: 0.79 mg/l: C, F, I). The control section of gill (A) represented hepatocytes with their uniform nuclei, gill arch (GA), filament cartilage (FC), normal pilar cell (PC), primary gill lamella (PGL), and secondary gill lamella (SGL) while treated fish (B, C) to heavy metals showed cytoplasmic vacuolation (V), fused lamella (FL), necrosis (NE), damaged lamella (DL), clubbed lamella (CL), short villi (SV),

degeneration of epithelium (DE), degeneration of piller cell (DPC), degeneration of blood vessel (DBV) and oedema (OED). The image of the control kidney (D) showed: G- Glomeruli, BC- Bowmen's Capsule, RT- Renal Tubule, HPT- Hematopoietic Tissue, and in exposed fish to copper (E) and zinc (F) showed vacuolation (V), GHY- Hyperplasia of Glomeruli, NBS- New Bowmen's Space, NT- Necrosis Tubule, DL- Lumen of Tubule Dilated, NE- Necrosis, HT- Hypertrophy of Tubule. Section of control liver (G) showed normal nucleus (NU), hepatocytes (HPC), kupffer cells (KC), S- Sinusoids and in treated sections (H, I): HAE- Hemorrhages, NE- Necrosis, DS- Distended Sinusoids, V- Vacuolation, PN- Pyknotic Nuclei. Images were acquired at 20x magnification.

REFERENCES

Abdel-Khalek, A. A., Badran, S. R., and Marie M.A.S. (2016). Toxicity evaluation of copper oxide bulk and nanoparticles in Nile tilapia, Oreochromis niloticus, using hematological, bioaccumulation and histological biomarkers. *Fish Physiology and Biochemistry*, **42**(4),1225-1236.

Abdel-Moneim, A. M., and Abdel-Mohsen, H. A. (2010). Ultrastructure changes in hepatocytes of catfish *Clariasgariepinus* from Lake Mariut, *Egyptian Journal of Environmental Biology,* **31**(5), 715-720.

Abdel-Tawwab, M. (2016). Effect of feed availability on susceptibility of Nile tilapia, *Oreochromis niloticus* (L.) to environmental zinc toxicity: Growth performance, biochemical response, and zinc bioaccumulation. *Aquaculture,* 464, 309-315.

Akahori, A., Jóźwiak, Z., Gabryelak, T., Gondko, R. (1999). Effect of zinc on carp (*Cyprinus carpio* L.) erythrocytes. *Comparative Biochemistry and Physiology,* 123, 209-215.

Annune, P. A., Olademeji, A. A., Ebele, S. O. (1962). Acute toxicity of zinc to the fingerlings of *Clariaslazera* (Cuvier and Valenciennes) and *Oreochromis niloticus*, Trewawas. *Journal of Aquatic Sciences,* 6, 19-22.

Chinni, S., Yallapragda, P. R. (2000). Toxicity of copper, cadmium, zinc and lead to *Penaeus indicus* post larvae: Effects of individual metals. *Journal of Environmental Biology,* 21, 255–258.

Ciji, P. P., Nandan, B. S. (2013). Toxicity of copper and zinc to *Puntius parrah* (Day, 1865). *Marine Environmental Research,* 93, 38-46.

Dhanapakiam, P., Ramasamy, V. R., Mini, J. (2006). Changes in the level of transaminases in Indian carp, *Labeorohita* exposed to sublethal concentration of tannery and distillery effluent. *Journal of Environmental Biology,* 27, 567-570.

Dutta, L., Rajbongshi, R., Sharma, S.R., Deka, P. (2016). Toxicity of heavy metal copper with reference to haematological alterations in a live cat fish species *Heteropneustesfossilis* (Bloch). *International Journal of Fauna and Biological Studies*, **3**(4), 36-38.

Çelik, E.S., Kaya, H., Yilmaz, S.,Akbulut, M.,Tulgar, A. (2013). Effects of zinc exposure on the accumulation, haematology and immunology of Mozambique tilapia, *Oreochromis mossambicus*. *African Journal of Biotechnology,* **12**(7),744-753.

Fadel, N. G., Gaber, H. S. (2007). Effect of exposure to pollutants on different organs of two fish species in Rossetta branch at River Nile, Egypt. *Comparative Clinical Pathology,* **20**(1), 364-389.

Fahmy, M. F. (2000). Potential genotoxicity in copper sulphate treated mice. *Cytologia,*65, 235-242.

Figueiredo-Fernandes, A., Ferreira-Cardoso, J. V., Garcia-Santos, S., Monteiro, S. M., Carrola, J., Matos, P., Fontaínhas-Fernandes, A. (2007). Histopathological changes in liver and gill epithelium of Nile tilapia, *Oreochromis niloticus*, exposed to waterborne copper. *Pesquisa VeterinariaBrasileira,* **27**(3), 103–109.

Finney, D. J., Probit analysis, 3rd Edn. Cambridge University Press UK, 1971, 25-26.

Ghalazy K.S. (1992). Haematological and physiological responses to sub lethal concentration of cadmium in a freshwater teleost, *Tilapia zillii. Water Air and Soil Pollution*, **64**(3), 551-559.

Griffin, R. B., Davis, B. K., Schlenk, D. (1999). Effect of simulated copper Sulphate therapy stress indicators in channel catfish. *Journal of Aquatic Animal Health, Oxford,* 11, 231-236.

Grosell, M., Nielsen, C., Bianchini, A. (2002). Sodium turnover rate determines sensitivity to acute copper and silver exposure in freshwater animals. *Comparative Biochemistry and Physiology Part C: Toxicology Pharmacology,* 133, 287-303.

Guo, H., Wang, Y., Cui, H., Ouyang, Y., Yang, T., Liu, C., Liu, X., Zhu, Y., Deng, H. (2022). Copper induces spleen damage through modulation of oxidative stress, apoptosis, DNA damage, and inflammation. *Biological Trace Element Research,* 200, 669–677.

Gupta, P., Srivastava, N. (2006). Effects of sublethal concentrations of zinc on histological changes and bioaccumulation of zinc by kidney of fish *Channa punctatus* (Bloch). *Journal of Environmental Biology,* **27**(2), 211-215.

Hedayati, A., Jahanbakhshi, A., Shaluei, F., Kolbadinezhad, S. M. (2013). Acute toxicity test of mercuric chloride ($HgCl_2$), lead chloride ($PbCl_2$) and zinc sulphate ($ZnSO_4$) in common carp (*Cyprinus carpio*). *Journal of Clinical Toxicology,* **3**(1), 1000156.

Hodson, P. V., Blunt, B. R., Spray, D. J. (1978). Chronic toxicity of water borne lead and dietary lead to rainbow trout. (*Balmogarnderi*) in lakeOntario water. *Water Research*, 12, 869-878.

Hoq, T., Haque, N. (2014). Effects of Sublethal Concentrations of Zinc (II) Sulphate Heptahydrate (Znso4.7H2O) On Blood Glucose Level of Freshwater Fish *Heteropneustesfossilis*. *International Journal of Scientific and Technology Research,* **3**(5), 2277-8616.

John, P. J. (2007).Alteration of certain blood parameters of freshwaterteleost *Mystusvittatus* after chronic exposure to Metasystox and Sevin. Fish *Physiology and Biochemistry*, 33, 15-20.

Joshi, P. K., Bose, M., Harish, D. (2002). Hematological changes in the blood of *Clariasbatrachus*exposed to mercuric chloride. *Journal of Ecotoxicology and Environmental Monitoring,* 12, 119-122.

Joshi, P. S. (2011). Impact of zinc sulphate on behavioural responses in the freshwater fish *Clariasbatrachus* (Linn.). *Online International Interdisciplinary Research Journal,* **1**(2), 76-82.

Gupta, K., Sachar, A., Gupta, K., Raina, S. (2009). Effect of lindane on haematological parameters of minor carp, *Labeoboga* (Ham.). *Bioscience Biotechnology Research Asia*, **6**(2), 695-702.

Kavitha, C., Malarvizhi, A., Senthil Kumaran, S., Ramesh, M. (2010). Toxicological effects of arsenate exposure on hematological, biochemical and liver transaminases activity in an Indian major carp, *Catlacatla*. *Food Chemical Toxicology*, 48, 2848-2854.

Kori-Siakpere, O., Ubogu, E. O. (2008). Sub-lethal haematological effects of Zinc on the freshwater fish, *Heteroclarias* sp. (Osteichthyes: Clariidae). *African Journal of Biotechnology,* **7**, 2068-2073.

Kumar, M., Prasad, M. R., Srivastva, K., Tripathi, S., Srivastva, A. K. (2010). Branchial histopathological study of Catfish *Heteropneustesfossilis* following exposure to purified neem extract, Azadirachtin. *World Journal of Zoology,* **5**(4), 239-243.

Lemly, A. D. (1993). Teratogenic effects of selenium in natural populations of freshwater fish. *Ecotoxicology and Environmental Safety,* **26**(2), 181-204.

Mgbenka, B. O., Oluah, N. S., Arungwa, A. A. (2005). Erythropoietic response and haematological parameters in the catfish *Clariasalpopunctatus* exposed to sublethal concentrations of actellic. *Ecotoxicology and Enviironmental Safety*, 62, 436-440.

Mishra, A.K., Mohanty, B. (2008). Acute toxicity impacts of hexavalent chromium on behavior and histopathology of gill, kidney and liver of the freshwater fish, *Channa punctatus* (Bloch). *Environmental Toxicology and Pharmacology*, **26**(2), 136-41.

Muthulingam, M., Revath, S. K., Ross, P. R., Ravichandran, S., Thenmozhi, P. (2015). Effect of heavy metal, nickel chloride on histopathological biomarkers in gill, liver and kidney of freshwater fish, *Oreochromis mossambicus* (Peters). *Life Science Journal,* **1**(3), 166-174.

Nordenson, N. (2004). White blood cell count and differential analysis. http://mydocuments/whitebloodcellcountanddifferentialahealthy-me.htm

Nussey, G., Van Vuren, J. H. J., du Preez, H. H. (2002). The effect of copper and zinc at neutral and acidic pH on the general haematology and osmoregulation of *Oreochromis mossambicus*. *African Journal of Aquatic Science*, 27, 61-84.

Olojo, E. A. A., Olurin, K. B., Mbaka, G., Oluwemimo, A. D. (2005). Histopathology of the gill and liver tissues of the African catfish *Clariasgariepinus* exposed to lead. *African Journal of Biotechnology,* **4**(1), 117-122.

Ortiz, J., De Canales, M., Sarasquete, C. (2003). Histopathological changes induced by lindane (γ-HCH) in various organs of fishes. *Scientia Marina,* **67**(1), 53-61.

Pacheco, M., Santos, M. A. Biotransformation, genotoxic and histopathological effects of environmental contaminants in European eel (*Anguilla anguilla* L.).

Ecotoxicology and Environmental Safety, **53**(3), 331-347.

Parmila, C.B., Rajan, M.R. (2020). Impact of bulk zinc oxide on Rohu *Labeorohita*. *International Research Journal of Natural and Applied Sciences*. **7**(11), 1-13

Raina, S., Sachar, A. (2014). Effect of Heavy Metal, Zinc and Carbamate Pesticide, Sevin on Haematological Parameters of Fish, *Labeo Boga.International Journal ofInnovative Research in Science, Engineering and Technology*, **3**(5): 12636-12644.

Ramesh, M., Sankaran, M., Veera-Gowtham, V. Krishnan, P.R. (2014).Hematological, biochemical and enzymological responses in an Indian major carp *Labeorohita* induced by sublethal concentration of waterborne selenite exposure. *Chemico-Biological Interactions*, 207, 67-73.

Sampath, K., James, R., Ali, K. M. A. (1998). Effects of copper and zinc on blood parameters and prediction of their recovery in *Oreochromis mossambicus* (Pisces: Cichlidae). *Indian Journal of Fisheries,* 45, 129-139.

Shenkar, J. M., Cherr, G. N. (1990). Toxicity of zinc and bleached kraft mill effluent to larval English sole (*Parophrysvetulus*) and topsmelt (*Atherinopsaffinis*). *Archives of Environmental Contamination and Toxicology,* **19**(5), 680-685.

Snieszko, S. F. (1960). Microhematocrit as a tool in fishery research and management, U.S. Fish and Wildlife Servey, *Special Scientific Report-Fisheries,* 341, 1-15.

Suganthi, P., Murali, M., Sadiq Bukhari, A., Syed Mohamed, H.E., Basu, H. Singhal, R.K. (2015). Haematological studies on freshwater Tilapia treated with ZnO nanoparticles. *Journal of Advance Applied Science Research,* **1**(1), 41-67.

Udotong, J. I., John, O. U. (2015). Histopathological changes in liver and muscle of tilapia fish from QIRE exposed to concentrations of heavy metals. *World Academy of Science Engineering and Technology*, **9**(6), 659-662.

Vinodhini, R., Narayanan, M. (2009). Heavy metal induced histopathological alterations in selected organs of the *Cyprinus carpio* L. (Common Carp). *International Journal of Environmental Research,* **3**(1), 95-100.

Wepener, V., Van Vuren, J. H. J., Du Preez, H. H. (2001). Uptake and distribution of a copper, iron and zinc mixture in gill, liver and plasma of freshwater teleosts, *Tilapia sparrmanii*. *Water SA,* 27, 99-108.

Witeska, M. Stress in fish: Hematological and immunological effects of heavy metals. *J Ichthyol,* 2005; 1: 35-41.