GAU Res. J. 1989. 15 (1) : 62–69

"Distribution of the Thickness, Cornification and Papillation of Epidermis, Solitary Lymph Nodules, Elastic Fibres and Melanin Pigment in the Prepuce of the Surti Buffalo

R. K. Das and K. N. Vyas

Department of Anatomy, College of Veterinary Science and Animal Husbandry, Gujarat Agricultural University, Anand Campus, Anand 388 001

ABSTRACT

Histological observations were carried out on the skin of preputial cavity including that of the glans penis in six adult and six Surti buffalo calves. The epidermis was thicker over the glans penis of the Surti buffalo as compared to that of the preputial cavity. The stratum corneum was marked in hairy, pigmented part of the cavity and over the glans penis. The solitary lymph nodules were found only in the skin reffected over the penis inside the cavity. Prominent net work of elastic fibres was seen in the dermis of hairy, pigmented skin of the preputial cavity and the skin covering the glans. The melanin pigment was present in the lower layer of epidermis, only in the hairy, initial part of the cavity.

(*Receievd on 4th Febru.* 1988)

INTRODUCTION

Trotter (1959) and Sisson (1955) stated that the preputial epithelial lining of the bull is stratified squamous and has a lightly cornfied superficial layer. Trotter (1959) further observed that the epithelium is slightly thicker in glans proper. Gupta *et al.* (1980) reported that in Murrah buffalo, the thickness of the epithelium and underlying connective tissue around the glans penis increases from calfhood to adulthood. Papillation of the lower border of the epithelium in the preputial skin was observed by Trotter (1959) and Bhardwaj and Calhoun (1961) in bulls and Copenhaver (1964) in man. Gupta *et al.* (1980) reported that in Murrah buffaloes, there are lympho cytic aggregation underlying the glans in adult animals. Sisson (1955) mentioned in bulls, that the penile layer presents lymph nodules in its caudal part. Dellmann and Brown (1976) mentioned that in Murrah ruminants both, the internal layer of the prepuce and skin covering the penis contains solitary lymph nodules. They further mentioned that the internal layer of the prepuce of dog has solitary lymph nodules. Gupta *et al.* (1980) reported the presence of good amount of

elastic fibres in the form of a net work in the glans of Murrah buffaloes. Similar findings were reported by Bharadwaj and Calhoun (1961) and Trotter (1959) in bulls. Copenhaver (1964) mentioned that in man, the hairy preputial skin has the melanin pigmentation in lower layers of the epithelium.

Reference was not available on the distribution of all these characters in various regions of the preputial cavity of the buffalo and hence this work was carried out.

MATERIALS AND METHODS

This study was carried out on the materials collected from 6 Surti buffalo calves (4-11 months of age) and 6 adult Surti buffaloes (above 4 years of age). The prepuce with the penis was kept in 10% neutral buffered formalin for 48 hrs. Then the tissues from six different levels of internal preputial skin and glans penis were collected as shown in Fig. 1. Longitudinal section (L.S.) were cut at the levels from hairy pigmented inner skin

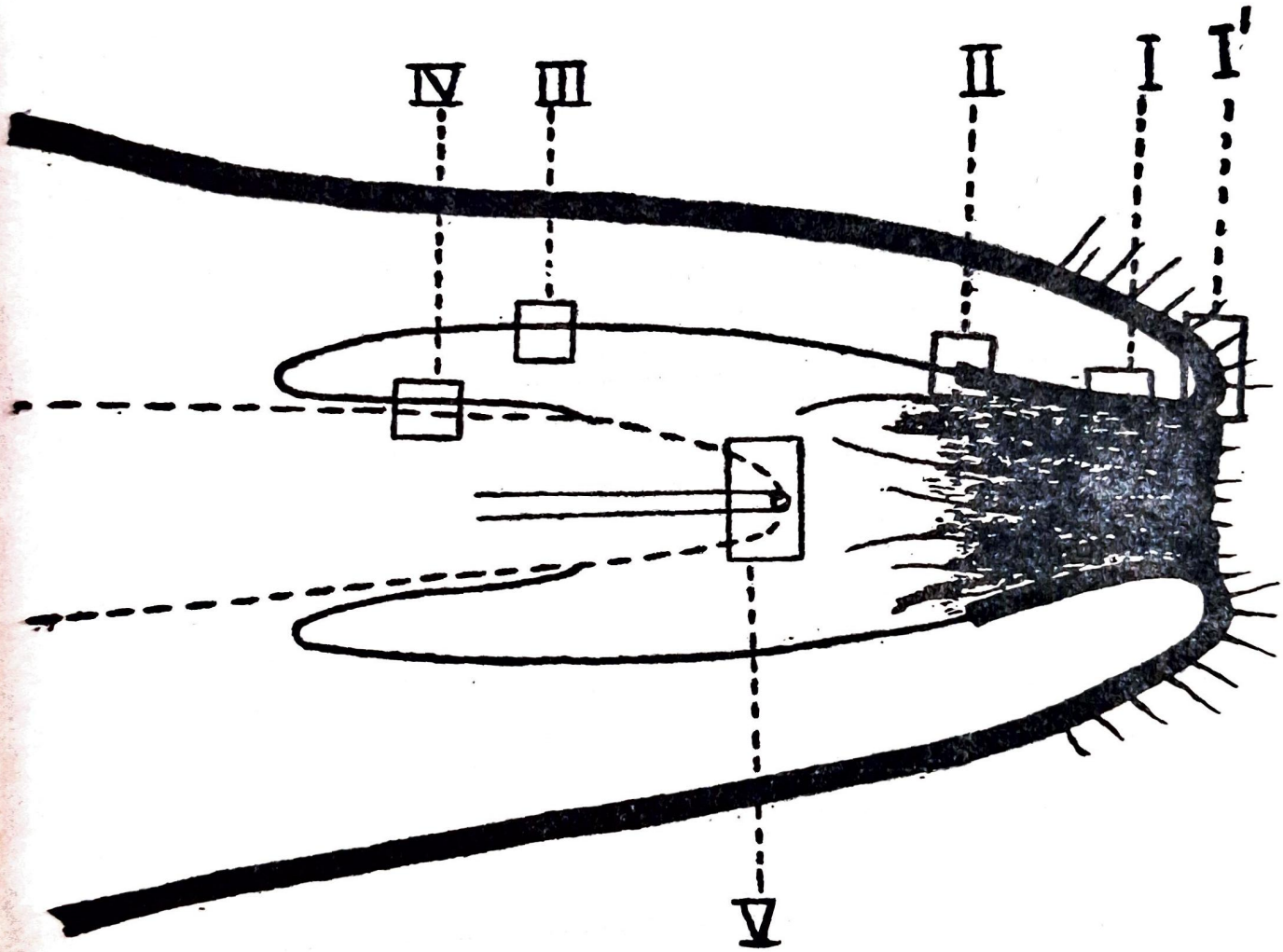

Fig. 1 : Schematic diagram of the sagittal section of the prepuce covering the glans penis in the Surti buffalo showing levels (I to V) for histological studies. An additional level (I') was also taken.

(I), preputial brim containing outer and inner skin (I') junction of inner, hairy pigmented and non-hairy, non-pigmented skin (II), non-hairy skin of fornix (III), skin reflected over the penis (IV) while transverse as well as longitudinal sections were cut from the glans penis (V). Frozen as well as paraffin sections were cut at 10 mm from all the levels and stained with the following stains :

(i) Harris' Hematoxylin and Eosin (H & E) staining (Luna, 1968) for general microscopic survey.

(ii) Hart's staining for elastic tissue (Luna, 1968).

(iii) Alocoholic picric acid staining (Nay and Jackson, 1973) to depict the melanin pigment in the epithelium.

RESULTS AND DISCUSSION

(a) Thickness and cornification of the epithelium at different levels (I to V) :

It was found that the epithelium was thicker over the glans proper as compared to that in the preputial cavity. Similar observations were reported by Trotter (1959) in the bull and Gupta *et al.* (1980) in the Murrah buffalo. The skin of the prepuce of all the regions as well as the skin over the glans, was cornified in calves and adults. Cornification was marked in levels I and V (Fig. 2 & 3). It was slight in levels II, III and IV. Cornification was slightly thicker in adults as compared to that in calves.

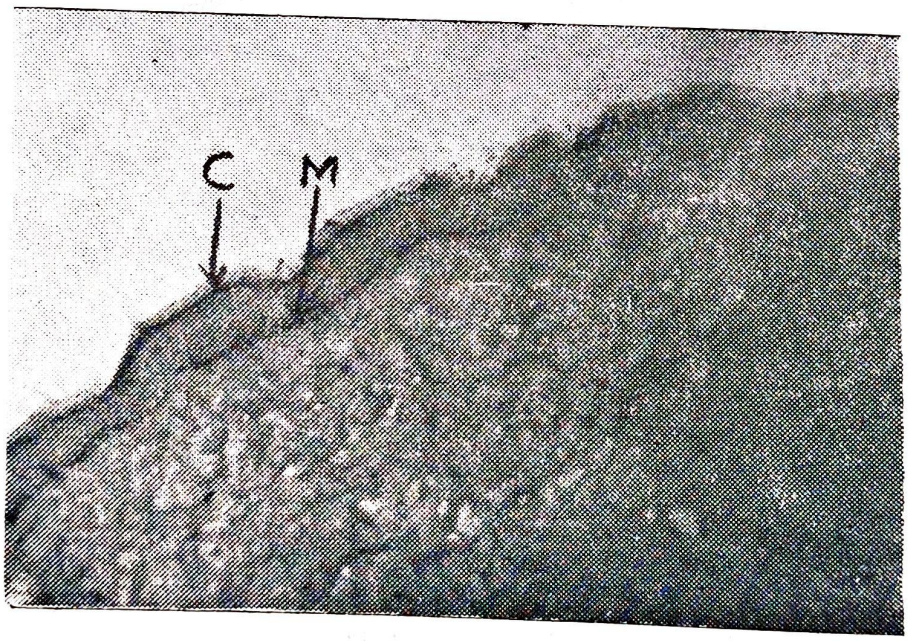

Fig. 2 : Longitudinal section of the inner, hairy, pigmented preputial skin (level I) of the Surti buffalo showing stratum corneum (C) and melanin pigment (M) in the lower layers of the epidermis. Picric acid saitn, x 60.

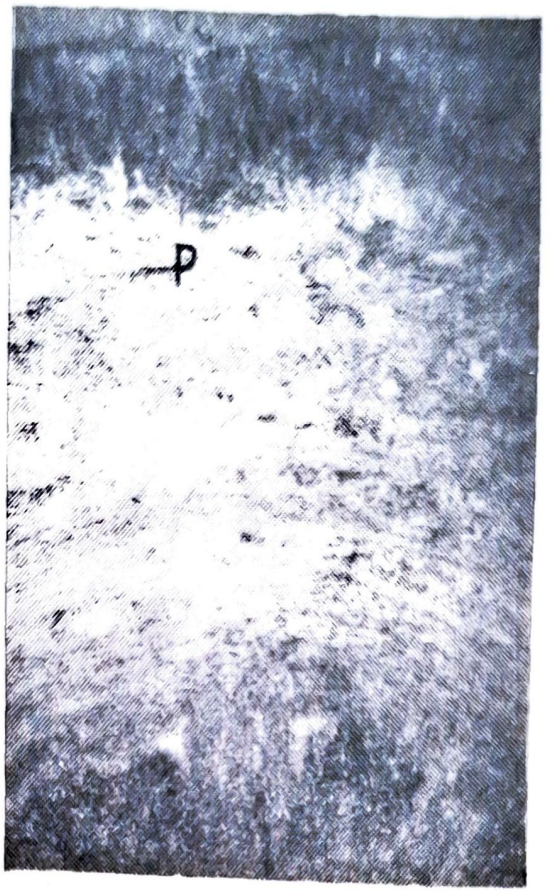

Fig. 3 : Transverse section of the glans penis of the Surti buffalo (level V) showing stratum corneum (C) and papillated lower border (P) of the epidermis. H & E stain x 30.

(b) Papillation of epithelium at different levels viz., I-V :

The lower border of the epithelium joining the dermis in Surti buffalo was not papillated in levels I and II (Fig. 2 & 6) but the papillation was observed in levels III, IV and V (Fig. 3 & 4). There was even secondary papillation in level III (Fig. 4). Such papillation was also observed in the preputial skin of bull by Trotter (1959) and Bharadwaj and Calhoun (1961). Similar papillation in preputial skin of man was also mentioned by Copenhaver (1964). The distribution of this papillation in various region of the preputial cavity was not mentioned in any reference.

(c) Presence of solitary lymph nodules :

In the present study it was found that in youngs as well as in adults, the non-hairy, non-pigmented skin covering the penis (Level IV) contained solitary lymph nodules in the caudal part (Fig. 5). This was in agreement with the description in the bull by Sisson (1955). But Dellemann and Brown (1976).

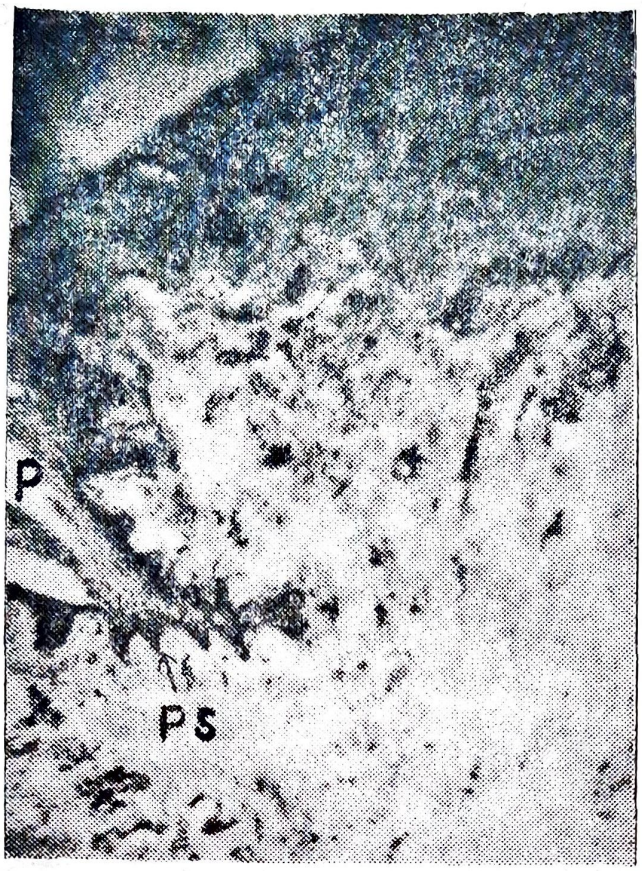

Fig. 4 : Longitudinal section of non-hairy, non-pigmented, inner preputial skin of the fornix (level III) showing papillation (P) and secondary papillation (PS) of the lower border of epidermis. H & E stain x 30.



Fig. 5 : Longitudinal section of the inner preputial non-hairy, non-pigmented skin reflected over the penis (level IV) showing solitary lymph nodules (LN) and papillation (P) of the lower border of the epidermis. H & E stain x 60.

mentioned that in ruminants, both the internal layer of the prepuce and skin covering the penis contains solitary lymph nodules. Gupta *et al.* (1980) reported that in Murrah buffaloes. there were many lymphocytic aggregations underlying the glans epithelium but such aggregations below the epithelium of glans, were not observed in the Surti buffalo calves as well as in adults.

(d) Presence of elastic fibres :

In the Surti buffalo under study, good amount of elastic fibres were seen in the dermis of the level I (Fig. 6) as well as in external layer of preputial skin in form of



Fig. 6 : Longitudinal section of hairy, pigmented skin of preputial cavity (level I) of the Surti buffalo showing net work of elastic fibres (E) in the dermis. Hart's stain x 60.

an interwoven network in calves and adults. In level V (glans) elastic fibres were seen in good amount (Fig. 7). This was in agreement with the findings of Gupta *et al.* (1980) in Murrah buffaloes, Bharadwaj and Calhoun (1961) and Trotter (1959) in bulls.



Fig. 7 : Transverse section of glans penis of the Surti buffalo (Level V) showing net work of elastic fibres (E) in the dermis and stratum corneum (C). Hart's stain x 60.

(e) Melanin pigmentation :

In the present study it was found that the hairy skin (level I) has melanin pigmentations in the lower layer of the epithelium (Fig. 2) in adults and calves. But the pigmentation was completely absent subsequently in other levels i.e. in fornix and preputial skin over the penis and over glans penis. Copenhaver (1964) mentioned the presence of such pigmentation in the hairy, preputial skin of man.

REFERENCES

Bharadwaj, M. B. and Calhoun, M. L, (1961). Mode of formation of the preputial cavity in Domestic Animal. *Am. J. Vet. Res.* **22** : 764-768.

Copenhaver, W. M. (1964). Bailey's Text Book of Histology, 5th edn. p.512. The Williams and Wilkins Company, Baltimore, USA.

Dellmann, H. and Brown, E. M., (1976). Text Book of Veterinary Histology. pp. 313-316. Lea & Febiger, Philadelphia, USA.

Gupta, A. N., Dhingra, L. D. Singh, Y. and Sharma D. N. (1980). Postnatal development of the penis in Murrah buffalo. A Gross Anatomical study. *Haryana Vet.* **19** : 1-16.

Luna, L. G. (1968). Manual of histological staining methods of the Armed Forces Institute of Pathology (3rd edn.). pp. 38-39. and 79. McGraw Hill Book Co., New York.

Nay, T. and Jackson, N. (1973). Effect of change in nutritional level on wool gollicle depth and bending in Australian Merinos. *Aust. J. Agric. Res.* **24** : 439-447.

Pearse, A. G. E. (1968). The histochemistry. Theoritical and applied 3rd edn. **2** : 214. J. A. Churchill Ltd., London.

Sisson, S. (1955). Sisson and Grossman's. The Anatomy of the Domestic Animals. Vol. 1 5th edn. (ed. R. Getty), 1975. The Mac Millan Company of India Ltd., Delhi, Bombay, Calcutta and Madras.

Trotter, D. M. (1959). Histology of the Genitalia of the Bovnie male. *Am. J. Vet. Res.* **59** : 221-223.